American Journal of Psychiatric Rehabilitation

Expert Opinion Article

A Comparative Study of Condylar Head Dimensions Effects of Gender, Age, and Side Differences

Ryaheen Ghazi Rashid[1]*, Sumaya Mohammed Mansor[2], Ziad Tarik[3]

[1]*BDS, MSc Oral and Maxillofacial Radiology, College of Dentistry, Bilad al-Rafidain University, Diyala 32001, Iraq
[2]BDS, MSc in Oral Pathology, Faculty of Dentistry, Diyala University, Iraq.
[3]Bachelor of Dental Surgery; Doctor of Philosophy in Maxillofacial Surgery, Faculty of Dentistry, Bilad al-Rafidain University, Diyala 32001, Iraq

***Corresponding Author:** Ryaheen Ghazi Rashid
*BDS, MSc Oral and Maxillofacial Radiology, College of Dentistry, Bilad al-Rafidain University, Diyala 32001, Iraq

Abstract
Condylar processes of the mandible are the major components of the temporomandibular joint (TMJ) with great intersubject variability in size and shape. This study uses cone-beam computed tomography (CBCT) to assess the effect of sex, chronological age, and side on the mediolateral dimension and vertical height of the condylar head. A good understanding of condylar head measurements is crucial to the diagnosis and treatment of TMJ disorders because morphometric differences may affect the position of the mandible and its dynamics of functioning. Understanding sex, age, and laterality related roles in these dimensional alterations would allow for reworking of treatment modalities and increased accuracy in presurgical planning, which in turn could result in a better patient outcome.
The study included fifty CBCT scans, with an equal split between each gender (twenty-five males and twenty-five females) aged twenty to forty years obtained from the radiology records at the Specialty Dental Center in Baquba city, Diyala, Iraq. Mediolateral width and vertical height of the condylar head were taken from the coronal CBCT scan slices and the data were categorized by age group; sex; and the lateral side, right or left. Statistical analyses reported independent-samples t-test, one-way ANOVA and Cohen's d to express effect magnitudes.
There was no significant sex effect on condylar width ($p = 0.319$ right; $p = 0.710$ left) or height ($p = 0.492$ right; $p = 0.079$ left), as shown by the results. However, age was significantly related to differences in mediolateral width ($p = 0.026$ right; $p = 0.016$ left) but not with vertical height ($p = 0.888$ right; $p = 0.216$ left). A substantial side-to-side asymmetry was not revealed in boys and girls for width ($p = 0.844$) and height ($p = 0.876$) with small effect size (Cohen's $d = 0.0199–0.0433$).
In conclusion, gender and side do not significantly influence the dimensions of the condylar head, as far as the measurement of condylar head is concern, whereas age does influences the mediolateral width but not with the vertical height. This information is essential to the knowledge of condylar morphology and the diagnosis and treatment planning of TMJ disorders.

Keyword: condylar head, gender, age, con beam computed tomography.

Introduction

The temporomandibular joint (TMJ) is an essential component in the craniofacial complex and serves a primary role in mastication, speech, and general mandibular function. One of the important aspects of its various components is the mandibular condyle which is implied in growth, articulation and adaptation to functional demands (**Chaurasia & Giri, 2017**). Morphology of the condylar head with variations in its width and height has been widely studied trying to understand the association with the factors of age, gender and side symmetry. These results are not only applicable in normal anatomical studies, but also of clinical interest in diagnosis and treatment of temporomandibular disorders (TMD), and maxillofacial trauma (**Alam et al., 2021**).
Formation of the condylar head morphology is dependent on genetic, functional, and environmental factors. There has been a consistent finding reported that condylar dimensions are larger in males than in females and this is attributed to differences in skeletal growth pattern and hormonal influences (**Matsumoto & Bolognese, 1995; El-Bahnasy et al., 2022**). Similarity, age has also been known to affect the condylar morphology, where evidence shows that the condyle goes through major modifications during growth and development, especially in the second and third decades of life (**Chaurasia & Giri, 2017**). Contrary to these findings the condylar dimensions and side symmetry are disputed. Some studies show no significant differences in condylar shape between right and left condyles (**Rodrigues et al. 2009**) whereas others point out subtle asymmetries with possible clinical relevance (**Alam et al. 2021**).
Cone-beam computed tomography (CBCT) is a very useful imaging modality for a comprehensive TMJ assessment. Its delivery of three dimensional (3D),

high resolution reconstructions, has positioned it as the gold standard for assessment of condylar shape and diversity (Al-Koshab et al., 2015). The objective of their study is to measure the condylar head's mediolateral width and height using CBCT and examine how the parameters relate to gender, age and the side. This study endeavored to contribute to growing body of literature on this done TMJ anatomy and clinical implications by providing a comprehensive analysis of these factors. There has been wide investigation of gender related differences in condylar morphology. The studies also indicate that condylar dimensions are larger in males compared to females and this is hypothesized to be due to differences in skeletal growth and hormonal growth (**Alam et al., 2021; El-Bahnasy, Magdy, & Riad, 2022**).

It was noted, for instance, that men exhibited a markedly greater mediolateral condylar dimension than women. (**Matsumoto & Bolognese, 1995**). Similarly, according to **Al Koshab, Nambiar, and John (2015**) condylar dimensions increased in males when using three-dimensional imaging. This supports previous knowledge that skeletal growth and remodeling are sex dependent, and particularly in cases of fast growth and hormonal changes, like puberty. Other factors that also affect condylar morphology include age. In later growth, the mandibular condyle also demonstrates significant growth and adaptive changes in line with the remaining craniofacial development (**Chaurasia & Giri, 2017; Alam et al., 2021**). Nevertheless, there are studies reporting different growth rates, which would lead to stability of condylar height before its width (**Rodrigues et al., 2009**). The role of age in condylar morphology is essential for identifying deviations from normal growth patterns to ensure such conditions are not pathological or developmental delays.

The other area of interest is the symmetry of the condylar head. While other studies Cone-beam computed tomography (CBCT) provides high-quality imaging for comprehensive TMJ assessment. Following its provision of high-resolution 3D reconstructions, it is now the gold standard in the analysis of condylar form and its differences (Al-Koshab et al., 2015). The purpose of this study is to measure…

Condylar width and no statistically significant difference was found between the right and left sides height, there are some that indicate very slight asymmetries that could relate to functional adaptations or pathologies (**Alam et al. 2021; Rodrigues et al. 2009**). The significance of the TMJ asymmetry assessment registered by orthodontic and orthopedic interventions and its pathogenesis due to occlusal imbalances, trauma or developmental conditions is clinically important (**Miller & Smidt, 1996**). Because CBCT is capable of delivering high resolution, three-dimensional images of the condylar head and adjacent structures, Cone-beam computed tomography (CBCT) has solidified its status as the definitive reference standard for evaluation of TMJ morphology. While the traditional imaging techniques have actually severe distortions in precise measurements, CBCT provides as well as the best options for measurement as well as enhancement of condylar width as well as elevation throughout different populations as well as clinical problems (**Al-Koshab et al., 2015; El-Bahnasy et al., 2022**). Studies with CBCT, taken more recently, have revealed CBCT's capability in identifying subtle morphologic differences which are related to age, sex and side (**Alam et al., 2021; Chaurasia & Giri, 2017**). The purpose of this study is to investigate the mediolateral the mediolateral and vertical dimensions of the condylar head," by CBCT imaging, and to study the effects of sex, age, and laterality on these values

Material and Methods

Study Population

The retrospective study included 50 patients (25 men, 25 women) aged 20 to 40 years. The normal occlusion was found in all subjects, who attended the Specialty Dental Center in Baquba (Diyala, Iraq) for a number of diagnostic reasons for which CBCT examination was required. Subjects who had undergone maxillofacial surgery or experienced maxillofacial trauma and who had facial asymmetry or TMJ disorders were excluded from the cohort.

CBCT Imaging

The CBCT datasets were obtained by using the new Tom Giano cone-beam unit (set at 110 kV, exposure time 24 s, tube current 5–7 mA, with a voxel resolution of 0.5 mm, and field of view of 16 × 14 cm). Coronal CBCT slices were evaluated for bilateral condylar measurements.

Linear measurements

Two linear measurements were obtained for each condylar head in the coronal CBCT section:

1. **Mediolateral width:** Condylar head The condylar head was measured bilaterally in the coronal plane from the most lateral landmark on the lateral aspect of the condylar head to the most medial landmark on the medial aspect of the condylar head (Line 1, Figure 1).

2. **Condylar height:** The condylar heads were measured on both sides, on coronal sections; the measurements started from the highest point of the upper aspect of the condylar head down to line 2 in the mediolateral reference plane (Figure 1).

Measurements were performed by a single calibrated examiner using cone-beam CT software to ensure consistency. Intra-examiner reliability was assessed by repeating measurements on ten randomly selected images one week apart, and an intra-examiner correlation coefficient (ICC) of 0.92 was achieved, indicating high reliability.

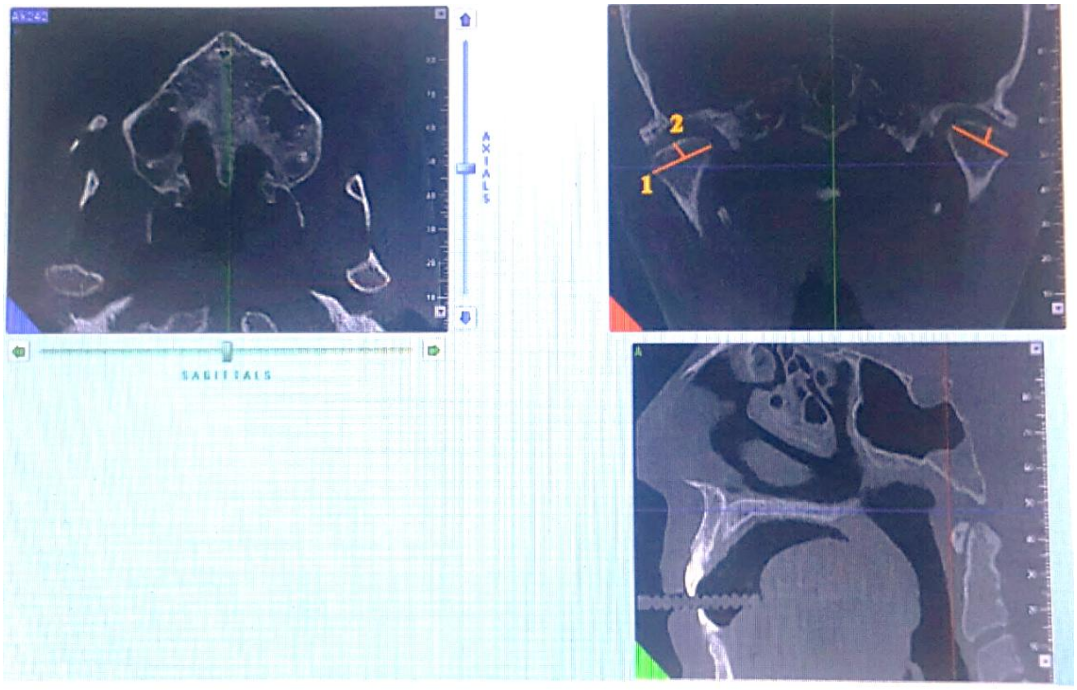

Fig. 1: MidwiPth Bilateral maximum diameter of the condylar head seen on a coronal CBCT section.

Statistical Analysis

Statistical evaluation of different comparison groups was performed with 2018 version of Statistical Analysis System (SAS) software. Comparisons of group means were made by means of one-way analysis of variance (ANOVA) with independent-samples t-tests and least significant difference (LSD) post hoc analyses. Effect size was calculated using Cohen's d, and the cut-offs were small (0.8). Results were considered statistically significant for $p < 0.05$.

Results

Effect of gender on Condylar Dimensions

The current study showed that the mediolateral dimension of the condylar head was significantly greater in males (right: 16.704 ± 2.839 mm; left: 16.713 ± 2.472 mm) than in females (right: 15.665 ± 2.234 mm; left: 15.797 ± 2.497 mm). for both right and left side. Comparisons of mean values shown statistically insignificant with p value (0.319) for the right side and p value = 0.710) for the left side. For testing the effect of gender on this measurement by Cohen's d, the effect seems to be weak for both the right and left side (0.409, 0.368). as detailed in Table 1

In addition, condylar head height was greater in males (right: 5.550 ± 1.247 mm; left: 5.205 ± 1.238 mm) than in females (right: 4.790 ± 1.246 mm; left: 4.322 ± 0.902 mm), but These differences were not statistically significant (right: p = 0.492; left: p = 0.079) and the effect sizes were small (Cohen's d = 0.409 on the right; 0.109 on the left) (Table 2).

Table 1: Comparison between Gender in condylar width

Measurements	Gender	Right (Mean ± SD, mm)	Left (Mean ± SD, mm)
Width	Male (n = 25)	16.704 ± 2.839	16.713 ± 2.472
	Female (n = 25)	15.665 ± 2.234	15.797 ± 2.497
	p-value	0.319	0.710
	Cohen's d	0.409	0.368

Table 2: Comparison between Gender in condylar head height

Measurements	Gender	Right (Mean ± SD, mm)	Left (Mean ± SD, mm)
Height	Female	4.790 ± 1.246	4.322 ± 0.902
	Male	5.550 ± 1.247	5.205 ± 1.238

Effect of age on width and height of condyle head

Age significantly, Medio-lateral width of condyle showed significant different between younger patients (20–30 years) widths Right: 17.0095 ± 2.67075 mm; left: 17.1810 ± 2.22343 mm) compared to older patients (30–40 years) (right: 15.5341 ± 2.27251 mm; left: 15.5805 ± 2.49542 mm) (right: p = 0.026; left: p = 0.016). Based on age, thereno significant effect on condylar height (right: p = 0.888; left: p = 0.216) as presented in Table 3.

Table 3: Comparison of condylar measurement in between different age groups

Side	Measurement	Age Group	N	Mean(mm)	SD (MM)	p-value
Right	Width	20-30 years	21	17.0095	2.67075	0.026*
		30-40 years	41	15.5341	2.27251	
	Height	20-30 years	21	5.3143	1.37233	0.888
		30-40 years	41	5.2634	1.26249	
Left	Width	20-30 years	21	17.1810	2.22343	0.016*
		30-40 years	41	15.5805	2.49542	
	Height	20-30 years	21	5.4952	1.36948	0.216
		30-40 years	41	5.1195	0.96985	

- Statistically significant ($p < 0.05$).

Effect of side difference on Condylar Dimensions

Mediolateral span and vertical measurements of the condylar head were compared between the right and left sides and the difference was not also significant (mediolateral span: p = 0.844; vertical measurements: p = 0.876). In addition, Cohen's d effect size analysis revealed a negligible effect across the numbers tested for both span and for height (d = 0.0433 for span; d = 0.0199 for height), as presented in Table 4.

Table 4: The side differences in the dimensions of the condyles

Measurements	Right (Mean ± SD, mm)	Left (Mean ± SD, mm)	p-value	Cohen's d
Width	16.033 ± 2.494	16.122 ± 0.318	0.844	0.0433
Height	5.280 ± 1.289	5.246 ± 1.124	0.876	0.0199

Discussion

The mandibular crest is a major site of facial growth and a critical determinant of TMJ function. This study used CBCT to evaluate the effects of sex, age, and lateral differences on the mediolateral width and height of the condylar head, providing insights into condylar morphology that may inform clinical practice. Our results indicate that males generally have greater mediolateral width and height compared to females, consistent with previous studies by Chaurasia and Giri (2017), Matsumoto and Bolognese (1995), Alma et al. (2021), Al-Koshab et al. (2015), and El-Bahnasy et al. (2022).

However, these differences were not statistically significant, suggesting that sex may not be a major determinant of condylar dimensions in this population. The weak effect sizes (Cohen's d: 0.109–0.409) further support this conclusion, suggesting little clinical significance for sex-based differences in condylar morphology. Age significantly influenced the mediolateral condylar width, with younger patients (20–30 years old) showing greater width than older patients (30–40 years old). This finding is consistent with Chaurasia and Giri (2017), who reported similar age-related differences in condylar width, likely reflecting growth-related changes or remodeling processes that occur early in adulthood. In contrast, condylar height did not show any significant variation with age, suggesting that vertical growth of the condylar head may stabilize earlier than mediolateral expansion. Tanaka, E., Detamore, M. S., & Mercuri, L. G. (2008).

Lateral differences (right versus left) had no significant effect on condylar width or height, consistent with Rodrigues et al. (2009), who reported consistency in the mediolateral condylar dimensions. However, our results contrast with Alma et al. (2021), who observed asymmetries in

condylar width between the two sides. These discrepancies may be attributed to differences in sample size, population characteristics, or measurement techniques. Additionally, our study found no association between age and condylar asymmetry, supporting Miller and Smidt (1996), who reported that age does not significantly contribute to condylar asymmetry.

Limitations of the current study are the small cohort size (n = 50) and the young age-range (20–40 years), which limits the generalization of the findings. Future studies should also include a larger sample of subjects over a greater age range as well as other parameters, such as occlusal classification or temporomandibular joint loading patterns, to more fully define the etiologic factors for condylar contour (Uysal et al., 2010).

Conclusion

Results The results showed that as per the CBCT, gender and side differences do not have a deleterious effect on the mediolateral dimension and height of the condylar head. Additionally, the mediolateral condylar width is highly influenced by age, and younger patients (20–30 years) have wider and similar height of the condyle, in contrast to older individuals (30–40 years). These results are not only informative for the newly described condylar morphology and its variation, they can also be engaged to diagnose the TMJ, orthodontics, and prosthetics. These finding were also confirmed with further studies on larger and more heterogeneous populations and after more research on other factors correlated to condylar size.

References

1. Alam, M. K., Ganji, K. K., Munisekhar, M. S., Alanazi, N. S., Alsharif, H. N., Iqbal, A., Patil, S., Amayet, N. B., & Sghaireen, M. (2021). A 3D cone beam computed tomography (CBCT) investigation of mandibular condyle morphometry: Gender determination, disparities, asymmetry assessment, and relationship with mandibular size. *Saudi Dental Journal, 33*(7), 687–692.
2. Al-Koshab, M., Nambiar, P., & John, J. (2015). Assessment of condyle and glenoid fossa morphology using CBCT in South-East Asians. *PLOS ONE, 10*(3), e0121682.
3. Chaurasia, A., & Giri, S. (2017). Evaluation of mandibular condyle morphology in Indian ethnics: A cross-sectional cone beam computed tomography study. *Journal of Oral Medicine, Oral Surgery, Oral Pathology and Oral Radiology, 3*(1), 17–22.
4. El-Bahnasy, S. S., Magdy, E., & Riad, D. (2022). Radiographic assessment of gender-related condylar head morphologic changes using a cone beam computed tomography: A retrospective study. *Egyptian Dental Journal, 68*(4), 3323–3331.
5. Matsumoto, M. A., & Bolognese, A. M. (1995). Bone morphology of the temporomandibular joint and its relation to dental occlusion. *Brazilian Dental Journal, 6*(2), 115–122.
6. Miller, V. J., & Smidt, A. (1996). Condylar asymmetry and age in patients with an Angle's Class II division 2 malocclusion. *Journal of Oral Rehabilitation, 23*(12), 712–715.
7. Rodrigues, A. F., Fraga, M. R., & Vitral, R. W. (2009). Computed tomography evaluation of the temporomandibular joint in Class I malocclusion patients: Condylar symmetry and condyle-fossa relationship. *American Journal of Orthodontics and Dentofacial Orthopedics, 136*(2), 192–198.
8. Uysal, T., Sisman, Y., Kurt, G., & Ramoglu, S. I. (2010). Condylar and ramal vertical asymmetry in adolescent patients with Class I and Class II subdivision malocclusions: A cone-beam computed tomography study. *American Journal of Orthodontics and Dentofacial Orthopedics, 138*(5), 542.e1–542.e12.
9. Tanaka, E., Detamore, M. S., & Mercuri, L. G. (2008). Degenerative disorders of the temporomandibular joint: Etiology, diagnosis, and treatment. *Journal of Dental Research, 87*(4), 296–307.